

Distribution of caprine arthritis encephalitis virus provirus, RNA, and antigen in the reproductive tract of one naturally and seven experimentally infected bucks

Andréia P. Turchetti^a, Juliana J. Paniago^a, Luciana F. da Costa^a, Juliano C.M. da Cruz^a, Gissandra F. Braz^a, Aurora M.G. Gouveia^a, Tatiane A. Paixão^b, Renato L. Santos^a, Marcos B. Heinemann^{a,*}

^a Escola de Veterinária, Universidade Federal de Minas Gerais, Av. Antônio Carlos, 6627, Pampulha, 31.270-901, Belo Horizonte, Brazil

^b Instituto de Ciências Biológicas, Universidade Federal de Minas Gerais, Pampulha, 31.270-901, Belo Horizonte, Brazil

ARTICLE INFO

Article history:

Received 4 January 2013

Received in revised form 16 July 2013

Accepted 17 July 2013

Keywords:

Lentivirus

Caprine arthritis encephalitis

Male genital tract

Goat

ABSTRACT

Caprine arthritis encephalitis is a worldwide, multisystemic disease caused by a small ruminant lentivirus. Although the main route of transmission is oral, detection of proviral DNA of the caprine arthritis encephalitis virus (CAEV) in caprine semen has been previously described. However, the presence of viral antigens in the male reproductive tract has apparently never been reported. The objective was to study lesions in the buck reproductive system and to detect, in these tissues, the presence of proviral DNA, viral RNA and CAEV antigens. Tissues from eight CAEV-infected bucks (one naturally and seven experimentally infected) were analyzed by histopathology, nested polymerase chain reaction, reverse transcriptase-polymerase chain reaction, and immunohistochemistry. Interstitial pneumonia, synovitis, and lesions in the male reproductive tract were detected in some of the bucks. Proviral DNA was detected in the lungs and joints as well as in the reproductive systems of all animals, whereas viral RNA was detected only in the genital tract of the naturally infected buck. Viral antigens were immunostained in most of the organs of the male reproductive tract. This report was apparently the first to clearly demonstrate CAEV antigen expression in the male reproductive tract, which indicates the possibility of venereal transmission of CAEV.

© 2013 Elsevier Inc. All rights reserved.

1. Introduction

Caprine arthritis encephalitis (CAE) is an important disease of goats, with worldwide distribution. The etiology is caprine arthritis encephalitis virus (CAEV), a small ruminant lentivirus (SRLV) with a single-stranded RNA genome that belongs to the *Retroviridae* family [1]. The CAEV can cause persistent infection in goats by inserting its genetic material into the host genome. In such cases, viral

RNA is inserted into the host genome in the form of proviral DNA (also known as the provirus [2]).

The CAEV can cause four basic forms of disease: (1) nervous, characterized by leukoencephalomyelitis; (2) arthritic; (3) respiratory, characterized by interstitial pneumonia; and (4) mammary [3]. The disease results in decreased production and economic losses in goat herds.

Infections usually occur during the first months of life by the oral route (ingestion of infected milk [4]). However, other forms of transmission have been reported. For example, transmission via aerosol and animal-to-animal contact can also occur [5]. As reviewed by Cortez-Romero et al. [6], there is evidence of possible uterine transmission because lentivirus proviral DNA has been detected

* Corresponding author. Tel.: +55 31 3409 2077; fax: +55 31 3409 2080.
E-mail address: marcosbryanheinemann@gmail.com (M.B. Heinemann).

in the female genital tract, and caprine uterine epithelial cells are susceptible to CAEV infection *in vivo* [7–12]. In addition, proviral DNA has been detected in the male genital tract [13,14] and in semen [13–19].

Because no effective vaccine or treatment for CAEV is available, control is based on preventing infection. Therefore, it is essential to understand all possible routes of transmission of the disease. The objectives of this study were to assess histopathological lesions and to detect proviral DNA, viral RNA and viral antigens in the lungs, synovia, and male reproductive tract of goats infected with CAEV.

2. Materials and methods

2.1. Animal handling and infection

Nine bucks (1 year old) from three breeds (one Alpine, four Toggenburg, and four Saanen) were acquired from commercial breeders and were kept on a farm at the Universidade Federal de Minas Gerais. One animal (Saanen; designated as buck 1) was naturally infected by CAEV (serologically positive by agar gel immunodiffusion [AGID] and polymerase chain reaction (PCR)-positive, with DNA extracted from the peripheral blood). The remaining eight bucks were negative (serologically negative by AGID and PCR-negative, with DNA extracted from the peripheral blood). Two seronegative bucks (bucks 2 and 3) were infected by intravenous injection of 2 mL of blood from buck 1. Five seronegative bucks (bucks 4–8) were infected with 2 mL of cultured synovial cells infected with the standard viral sample of Cork (10^6 tissue culture infectious dose 50/mL) and administered by intravenous injection (jugular vein). One animal (Toggenburg) was kept uninfected as a negative control. Every 2 weeks, blood samples were tested (PCR and AGID). The bucks were kept indoors in individual stalls and were isolated from each other throughout the experimental period. Their housing conditions were clean and comfortable and they were fed hay, 800 g of balanced concentrate with 18% crude protein, a mineral mixture, and water *ad libitum*. Eighteen months after inoculation, all bucks were euthanized and necropsied. Euthanasia was performed by intravenous injection of thiopental until a deep level of anesthesia was obtained, followed by electrocution, according to the recommendations of the Institutional Ethics Committee of the Universidade Federal de Minas Gerais (license 183/06) and the Brazilian Federal Board of Veterinary Medicine.

2.2. Histopathology and immunohistochemistry

Samples of lung, the synovial membrane of the carpal joint (only for histopathology), bulbourethral gland, prostate, vesicular glands, the ampulla of the deferent duct, epididymis (divided into the head, body [sampled at its midpoint] and tail), and the testis were collected. Tissues were fixed by immersion in 10% buffered formalin and were processed using the paraffin-embedding technique. For histopathological analysis, 5- μ m sections were stained with hematoxylin and eosin (HE). The distribution, extent, type, and intensity of inflammatory infiltrations were

assessed. Lesions of the lung and synovial membrane were classified according to intensity: (–) absent, (+) very mild, (++) mild, and (+++) moderate. For immunohistochemistry of samples that were positive by nested PCR, 5- μ m sections, fixed as described previously, were labeled using the peroxidase method (Dako North America Inc., Carpinteria, CA). The immunohistochemistry protocol used in this study has been described [20]. Briefly, a primary monoclonal immunoglobulin G1 antibody against p28 of CAEV (CAEP13B1; VMRD, Inc. Pullman, WA) was diluted 1:100 and was applied to sections overnight at 4 °C. For this assessment, 3-amino-9-ethylcarbazole served as the chromogen and Mayer's hematoxylin as the counterstain. In the negative controls, the primary antibody was omitted. Tissues from an uninfected animal were also used as negative controls. Additionally, the negative controls also included replacing the primary anti-CAE antibody with an isotypical monoclonal antibody, anti-*Salmonella enterica* serotype Typhimurium LPS (ab8274; Abcam, Cambridge, MA). The positive controls were lung sections from CAEV-seropositive goats.

2.3. Nested PCR and reverse transcriptase (RT)-PCR procedures

Samples of the lung, bulbourethral gland, prostate, vesicular gland, ampulla of the deferent duct, epididymis (head, body, and tail), and testis were collected. The fragments were stored at –80 °C and were processed for DNA extraction by the guanidine method [21] and for RNA extraction using Trizol, according to the manufacturer's instructions (Invitrogen, Grand Island, NY). Extracted RNA samples were pretreated with DNase (Invitrogen) before cDNA synthesis, using the primer GAG2 (5'-TCCTACCCCC ATAATTTGATCCAC-3'), according to the protocol of the SuperScript kit (Invitrogen). Five DNase-treated RNA samples and five untreated RNA samples were used directly as templates for PCR amplification to ensure the DNase treatment was effective. For nested PCR, the following pair of external primers was used for the first round of amplification: GAG1 (5'-CAAGCAGCAGGAGGGAGAAGCTG-3', nucleotides 953–975) and GAG2 (5'-TCCTACCCCC ATAATTTGATCCAC-3', nucleotides 1249–1226), generating a 297 base pair (bp) product. The internal primers—GAG 3 (5'-GTTCCAGCAACTGCAACAGTAGCAATG-3' nucleotides 997–1024) and GAG4 (5' ACCTTTCTGCTTCTTCATTTAA TTTCCC-3' nucleotides 1181–1154)—were used for the second round of amplification, generating a product of 185 bp [18]. Amplification was performed using a PTC 100 cyler under the following conditions (for both rounds): an initial denaturation at 94 °C for 3 minutes, followed by a series of 35 cycles with 30 seconds of denaturation at 94 °C, 30 seconds of annealing at 56 °C, and 30 seconds of extension at 72 °C. The last cycle was followed by a final extension at 72 °C for 7 minutes. For RT-PCR, the primers were used from the first round of amplification of the nested PCR. One microgram of RNA was used for cDNA synthesis. Thirty milliliters of Supermix (Invitrogen) and 0.5 to 1 μ g of DNA was used per reaction. The PCR products were resolved by electrophoresis on agarose gel, and bands of 185 bp were considered positive.

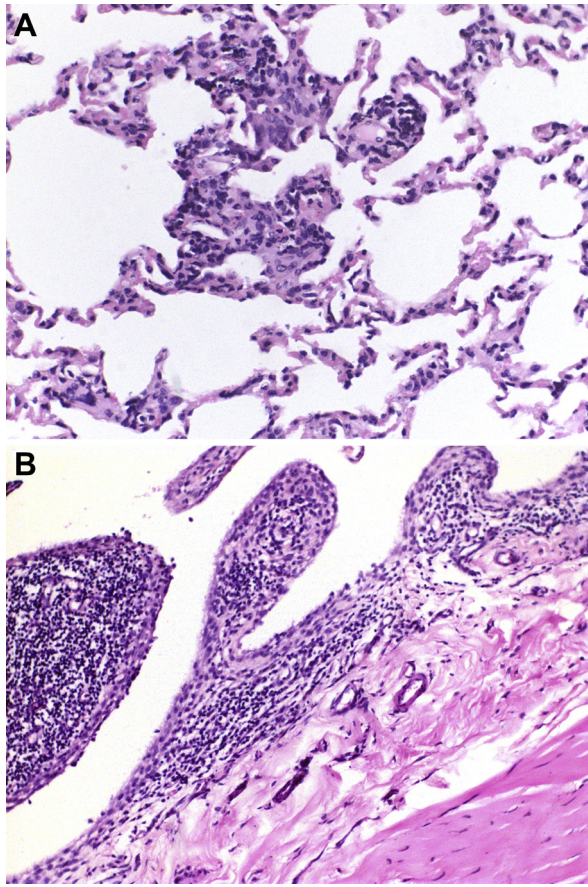


Fig. 1. Histopathological findings from the lungs and carpal joints of bucks infected with caprine arthritis encephalitis virus. (A) Lymphohistiocytic interstitial pneumonia, multifocal moderate. Hematoxylin and eosin (HE), 40 \times . (B) Diffuse moderate lymphohistioplasmacytic synovitis. HE, 20 \times .

3. Results

3.1. Clinical and histopathological findings

No clinical signs were observed in the infected bucks or in the negative control animal. Histologically, five of eight lungs had thick alveolar septa with lymphohistiocytic inflammatory infiltration and some neutrophils in a multifocal distribution (Fig. 1A). Three of eight carpal joints had a diffusely thickened synovial membrane, with formation of

Table 1

Histopathological lesions of tissues from bucks infected with caprine arthritis encephalitis virus.

Tissue	Buck							
	1	2	3	4	5	6	7	8
Carpal joint	+++	–	+	–	++	–	–	–
Lung	++	++	+	–	+	–	–	+

Buck 1: naturally infected; bucks 2 and 3: infected experimentally with inoculation of the blood of buck 1; bucks 4 to 8: infected experimentally with inoculation of infected cell culture. The lesions were classified as: absent (–), very discrete (+), discrete (++), and moderate (+++).

papillary projections associated with lymphohistioplasmacytic inflammatory infiltration into the stroma region (Fig. 1B). The intensity of the lesions varied as described (Table 1).

Bucks 1, 2, and 3 had lesions in the genital tract. Buck 1 had testicular degeneration and spermatogenic arrest, characterized by the following: spermatid degeneration and spermatogonias with vacuolated cytoplasm and pyknotic nuclei, with complete multifocal loss of the seminiferous epithelium in 20% of tubules and mild multifocal interstitial fibroplasia; less than 5% of the seminiferous tubules dilated and densely filled with sperm, characterized by mild multifocal spermiostasis; lymphoplasmacytic inflammatory infiltration in the interstitium with multifocal epithelioid macrophages and multifocal mineralization within the epithelium and lumen, beneath the basement membrane and in the interstitium at the head of the epididymis, affecting approximately 35% of the cross-sections of the ducts (Fig. 2A); and spermatic granulomas, characterized by sperm extravasation resulting from basal membrane rupture, associated with lymphoplasmacytic inflammatory interstitial infiltrates with multifocal epithelioid macrophages in the body of the epididymis. Some

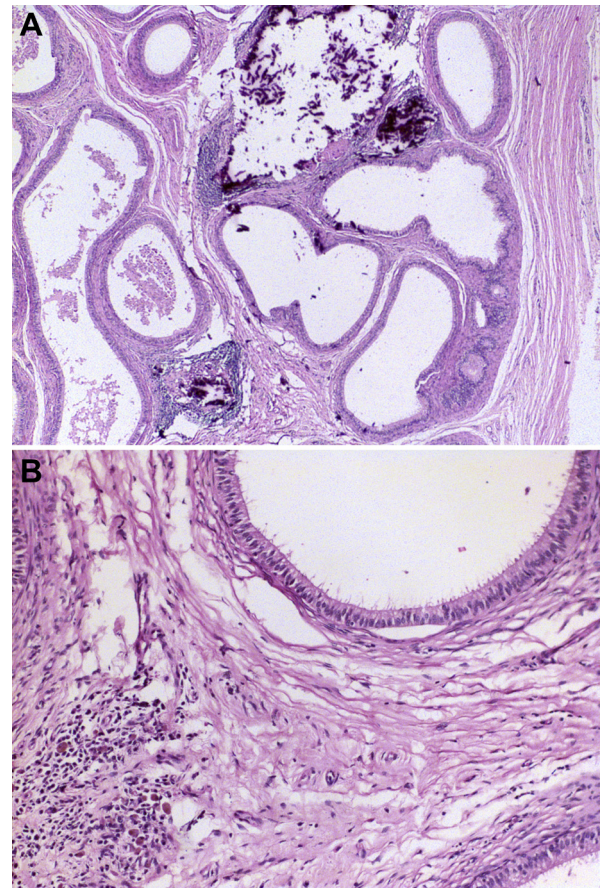


Fig. 2. Histopathological findings of epididymitis from bucks infected with caprine arthritis encephalitis virus. (A) Multifocal mononuclear epididymitis associated with multifocal mineralization. Hematoxylin and eosin (HE), 4 \times . (B) Multifocal epididymitis with a predominance of macrophages. HE, 20 \times .

macrophages contained intracytoplasmic yellow pigment (Fig. 2B), indicating granulomatous epididymitis of the head and body of the epididymis. Buck 2 had areas of spermiostasis at the head of the epididymis, affecting a few (approximately 10%) markedly dilated sections of the epididymal duct, which were densely filled with sperm and associated with adjacent mild neutrophilic interstitial infiltration with a few lymphocytes. Buck 3 had multifocal areas of mild testicular mineralization within the lumen in less than 5% of the tubules and mild hyperplasia of the epithelium in approximately 30% of the epididymal duct, associated with mild intraepithelial vacuolization at the head of the epididymis.

3.2. Nested PCR and RT-PCR

The presence of proviral DNA and viral RNA in tissues were investigated by nested PCR and RT-PCR, respectively (Table 2). The uninfected control animal remained negative by PCR throughout the experimental period.

The naturally infected animal (buck 1) had the most positive tissues, as determined by nested PCR. With the exception of the vesicular gland, all other tissues from buck 1 were positive. Indeed, this was the only buck that had RT-PCR-positive samples. The testis, ampulla of the deferent duct, and body of the epididymis were positive for CAEV RNA. Bucks 2 to 8 had proviral DNA detected in at least one of their tissues. Bucks 6 and 7 had the greatest number of

positive samples. Except for the vesicular gland, which was negative in all bucks, all of the other tissues were positive for proviral DNA in at least two animals. The bodies of the epididymis and bulbourethral glands were positive six of eight bucks.

3.3. Immunohistochemistry

Negative controls, both from the uninfected buck and from the samples in which the primary anti-CAEV antibody was replaced by an isotypical monoclonal antibody, anti-*Salmonella enterica* serotype Typhimurium LPS, yielded no specific positive staining, with minimal diffuse background staining, particularly at the edges of the sections. In the positive control, there was marked cytosolic immunostaining of up to 50% of the epithelial cells of the bronchial glands. There was also mild staining in the bronchial and bronchiolar epithelia. Immunostaining was characterized by a cytoplasmic granular material up to 3 µm in diameter, which was predominantly perinuclear, at the apical side of the cytosol. All tissues from the naturally infected animal (buck 1) and tissues from other animals that were positive by nested PCR underwent immunohistochemistry for detection of viral antigens (Table 2). Buck 1 had the most immunostained tissues (five of nine): the lung (Fig. 3); the ampulla of the deferent duct; the body of the epididymis (Fig. 3); the bulbourethral gland; and the prostate. Both tissues from buck 2 that were

Table 2
Nested PCR, RT-PCR, and IHC of tissues from bucks infected with CAEV.

Buck	Test	Tissues								
		Lung	VG	Testis	AD	ET	EH	EB	BG	Prostate
NC	N-PCR	–	–	–	–	–	–	–	–	–
	RTPCR	–	–	–	–	–	–	–	–	–
	IHC	–	–	–	–	–	–	–	–	–
1	N-PCR	+	–	+	+	+	+	+	+	+
	RTPCR	+	–	+	+	–	–	+	–	–
	IHC	+	–	–	+	–	–	+	+	+
2	N-PCR	–	–	–	–	–	+	–	+	–
	RTPCR	–	–	–	–	–	–	–	–	–
	IHC	ND	ND	ND	ND	ND	+	ND	+	ND
3	N-PCR	–	–	+	+	–	–	+	–	–
	RTPCR	–	–	–	–	–	–	–	–	–
	IHC	ND	ND	–	–	ND	ND	+	ND	ND
4	N-PCR	+	–	–	–	–	–	+	+	–
	RTPCR	–	–	–	–	–	–	–	–	–
	IHC	–	ND	ND	ND	ND	ND	–	–	ND
5	N-PCR	–	–	–	–	–	–	–	+	–
	RTPCR	–	–	–	–	–	–	–	–	–
	IHC	ND	ND	ND	ND	ND	ND	ND	+	ND
6	N-PCR	+	–	–	–	–	+	+	+	+
	RTPCR	–	–	–	–	–	–	–	–	–
	IHC	–	ND	ND	ND	ND	–	–	–	–
7	N-PCR	–	–	+	+	–	–	+	+	+
	RTPCR	–	–	–	–	–	–	–	–	–
	IHC	ND	ND	–	–	ND	ND	–	+	–
8	N-PCR	+	–	+	–	–	–	–	+	–
	RTPCR	–	–	–	–	–	–	–	–	–
	IHC	+	ND	–	ND	ND	ND	ND	–	ND

Bucks: 1, naturally infected; 2 and 3, infected experimentally with inoculation of the blood of animal 1; and 4 to 8, infected experimentally with inoculation of infected cell culture.

Abbreviations: AD, ampulla of the deferent duct; BG, bulbourethral gland; CAEV, caprine arthritis encephalitis virus; EB, epididymis body; EH, epididymis head; ET, epididymis tail; IHC, detection of CAEV protein by immunohistochemistry; NC, negative control; ND, not determined; N-PCR, detection of proviral DNA by nested polymerase chain reaction; RTPCR, detection of viral RNA by reverse transcriptase-polymerase chain reaction; VG, vesicular gland.

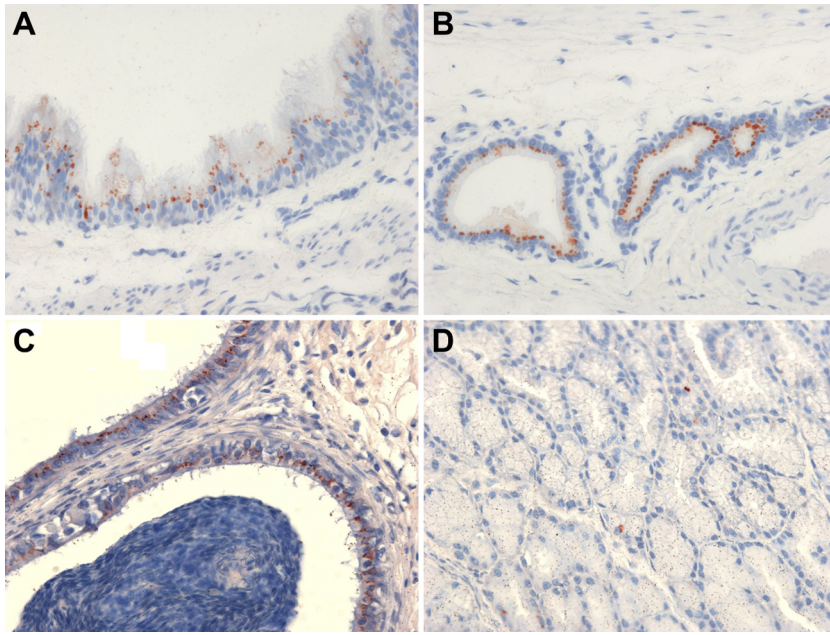


Fig. 3. Immunohistochemical findings of tissues from bucks infected with caprine arthritis encephalitis virus. Immunostained granular cytoplasmic antigens up to 3 μm in diameter, predominantly perinuclear, on the apical side of the cytosol of epithelial cells in the bronchial epithelium (A), bronchial gland (B), epididymis (C), and bulbourethral gland (D). Immunohistochemistry 40 \times .

positive by nested PCR were also positive by immunohistochemistry. Bucks 3, 5, 7, and 8 had only one immunostained tissue sample, whereas bucks 4 and 6 had no viral antigens detected in the tissues on which immunohistochemistry was performed. In the animals in which immunohistochemistry was performed on the vesicular glands, testis and tails of the epididymis, there was no detection of the antigen. Similar to the positive control, in all positive tissues, epithelial cells were the most frequently immunostained cell type, with immunostained cytoplasmic granular material up to 3 μm in diameter, predominantly perinuclear, on the apical side of the cytosol (Fig. 3). In the lungs, there was marked cytosolic immunostaining of 40% to 50% of the epithelial cells of the bronchial glands. In the bronchial epithelium, approximately 10% of the cells were stained, whereas approximately 5% of the bronchiolar epithelium had immunostained cytoplasmic antigens. Epididymal ductal epithelial cells in the head and body of the epididymis also had marked cytosolic immunostaining, varying from 40% to 70% of the cells stained, whereas immunostaining was less intense (approximately 5%) in the epithelial cells of the ampulla of the deferent duct. The cytoplasm of the prostate tubular-alveolar and bulbourethral gland epithelium was mildly immunostained (<5% staining). Rare (<2%) interstitial cells were immunostained in the prostate and bulbourethral glands. There was no immunostaining in areas with inflammatory infiltrates in the epididymis.

4. Discussion

The histopathological lesions in the lungs and joints observed in this study were compatible with CAEV

infection. Interstitial pneumonia and synovitis are the respiratory and arthritic manifestations, respectively, which are considered common in this disease [3,22].

Although lymphoplasmacytic inflammatory infiltration is a more common finding in the head of the epididymis; it is usually associated with spermatic granulomas because of obstruction in the efferent duct, especially in hornless goats [23]. However, in buck 1, this lesion was observed in the body of epididymis. As reported, in the head of the epididymis, there was also an inflammatory process; therefore, this finding was not considered atypical. Chronic inflammation and fibrosis of the epididymis can obstruct the duct lumen and cause spermiostasis [23]. The lesion observed should therefore be considered as a consequence of epididymitis.

In addition to the lungs, the naturally infected goat (buck 1) was positive by RT-PCR in three tissues of the reproductive tract. This naturally infected animal was the only one in which viral RNA was confirmed, and it was the animal with the greatest number of tissues stained by immunohistochemistry; perhaps because of a longer duration of CAEV infection. Differences in the PCR, RT-PCR, and immunohistochemistry results were expected because these techniques have differences in sensitivity and targets for detection or amplification. However, there were no apparent differences between animals experimentally infected with blood from a naturally infected animal or those infected with cultured CAEV-infected cells.

This was apparently the first time that CAEV RNA was detected by RT-PCR, and this study is the first report of CAEV antigens in the male reproductive tract, which is an important step in raising the possibility of its venereal transmission. These findings clearly demonstrated viral replication in these tissues and not only proviral DNA. The

productive state of CAEV was recently demonstrated by viral RNA detection in the tissues of the male genital system by *in situ* hybridization [13]. However, this was apparently the first study to demonstrate viral antigens in genital organs.

Some authors have demonstrated the presence of proviral DNA in the semen, and the results here corroborate their findings [13–19]. Because the CAEV has a tropism for monocytes, macrophages, and dendritic cells, any biological secretion or excretion, including semen, could be a source of infection by carrying inflammatory cells [24]. Therefore, immunohistochemical staining of macrophages might be expected in reproductive tissues. However, immunostained macrophages were not observed, even in areas with histiocytic inflammatory infiltration, whereas epithelial cells were the cell type most often immunostained. Nevertheless, in previous studies, epithelial cells from several tissues were infected [25]. In this study, the only exception for the detection of CAEV antigens in epithelial cells was the finding of rare immunostained cells in the interstitium of the prostate and bulbourethral glands, which might have been macrophages. Therefore, the proviral DNA found in semen could be explained by CAEV infection of epithelial cells and their desquamation and secretion of seminal fluid in the genital tract, as demonstrated by immunohistochemistry in this study. A comparison can be drawn between the findings of this study and those of previous reports regarding other small ruminant retroviruses in biological secretions. For example, the Jaagsiekte sheep retrovirus infects lung epithelial cells, resulting in adenocarcinoma development and an increase in lung fluid production, with high concentrations of infective virus [26,27].

We inferred that there is a possibility of sexual transmission of CAEV, either by AI or natural service. Contamination of the uterus has been demonstrated, either naturally or through AI with infected semen [12]. These results reinforced the need for CAEV-free males, which are regularly tested, to prevent and control the disease in goat herds.

In conclusion, we demonstrated the presence of CAEV proviral DNA, viral RNA, and viral antigens in genital organs of male goats. Therefore, CAEV was multiplying in the reproductive tracts of these animals. The presence of viral RNA and viral antigens in male genital organs indicated the potential for venereal transmission of CAEV.

Acknowledgments

This study was supported by Conselho Nacional de Desenvolvimento Científico e Tecnológico, Brasília, Brazil, Fundação de Amparo a Pesquisa do Estado de Minas Gerais, Coordenação de Aperfeiçoamento de Pessoal de Nível Superior, and Pró-Reitoria de Pesquisa da Universidade Federal de Minas Gerais.

A.P.T. performed the RT-PCR, immunohistochemistry, and interpretation of data and drafted the manuscript; J.J.P. performed the nested PCR, histopathological analysis and interpretation of the data; L.F.C. performed the RT-PCR; J.C.M.C., A.M.G.G., and G.F.B. made substantive contributions to the conception, design, and acquisition of the data;

A.M.G.G., T.A.P., R.L.S., and M.B.H. made substantive contributions to the conception and design, and they revised the manuscript critically. All authors have approved the final article.

References

- [1] Cheevers WP, Roberson S, Klevjer-Anderson P, Crawford TB. Characterization of caprine arthritis-encephalitis virus: a retrovirus of goats. *Arch Virol* 1981;67:111–7.
- [2] Zink MC, Narayan O, Kennedy PG, Clements JE. Pathogenesis of visna/maedi and caprine arthritis-encephalitis: new leads on the mechanism of restricted virus replication and persistent inflammation. *Vet Immunol Immunopathol* 1987;15:167–80.
- [3] Narayan O, Cork LC. Lentiviral diseases of sheep and goats. Chronic pneumonia, leukoencephalomyelitis and arthritis. *Rev Infect Dis* 1985;7:89–98.
- [4] Adams DS, Klevjer-Anderson P, Carlson JL, McGuire TC, Gorham JR. Transmission and control of caprine arthritis-encephalitis virus. *Am J Vet Res* 1983;44:1670–5.
- [5] Blacklaws BA, Berriatua E, Torsteinsdottir S, Watt NJ, de Andres D, Klein D, et al. Transmission of small ruminant lentiviruses. *Vet Microbiol* 2004;101:199–208.
- [6] Cortez-Romero C, Pellerin JL, Ali-Ahmad MZ, Chebloune Y, Gallegos-Sánchez J, Lamara A, et al. The risk of small ruminant lentivirus (SRLV) transmission with reproductive biotechnologies: state-of-the-art review. *Theriogenology* 2013;79:1–9.
- [7] Barlough J, East N, Rowe JD, Van Hoosear K, DeRock E, Bigornia L, et al. Double-nested polymerase chain reaction for detection of caprine arthritis-encephalitis virus proviral DNA in blood, milk and tissues of infected goats. *J Virol Methods* 1994;50:101–14.
- [8] Leroux C, Lerondelle C, Chastang J, Mornex JF. RT-PCR detection of lentivirus in milk or mammary secretions of sheep or goats from infected flocks. *Vet Res* 1997;28:115–21.
- [9] Fieni F, Rowe J, Van Hoosear K, Burucoa C, Oppenheim S, Anderson G, et al. Presence of caprine arthritis-encephalitis virus (CAEV) proviral DNA in genital tract tissues of superovulated dairy goat does. *Theriogenology* 2003;59:1515–23.
- [10] Cortez Romero C, Fieni F, Roux C, Russo P, Guibert JM, Guiguen F, et al. Detection of ovine lentivirus in the cumulus cells, but not in the oocytes or follicular fluid, of naturally infected sheep. *Theriogenology* 2006;66:1131–9.
- [11] Cortez-Romero C, Fieni F, Russo P, Pepin M, Roux C, Pellerin JL. Presence of Maedi Visna virus (MVV)-proviral DNA in the genital tissues of naturally infected ewes. *Reprod Dom Anim* 2011;46:e1–6.
- [12] Ali Al Ahmad MZ, Dubreil L, Chatagnon G, Khayli Z, Theret M, Martignat L, et al. Goat uterine epithelial cells are susceptible to infection with Caprine Arthritis Encephalitis Virus (CAEV) *in vivo*. *Vet Res* 2012;43:5.
- [13] Ali Al Ahmad MZ, Fieni F, Pellerin JL, Guiguen F, Chereil Y, Chatagnon G, et al. Detection of viral genomes of caprine arthritis-encephalitis virus (CAEV) in semen and in genital tract tissues of male goat. *Theriogenology* 2008;69:473–80.
- [14] Peterson K, Brinkhof J, Houwers DJ, Colenbrander B, Gadella BM. Presence of pro-lentiviral DNA in male sexual organs and ejaculates of small ruminants. *Theriogenology* 2008;69:433–42.
- [15] Travassos C, Benoît C, Valas S, da Silva AG, Perrin G. Caprine arthritis-encephalitis virus in semen of naturally infected bucks. *Small Rumin Res* 1999;32:101–6.
- [16] Andrioli A, Gouveia AMG, Pinheiro RR, Rocha MA, Martins AS, Santos DO. Detecção do DNA pró-viral do lentivírus caprino em sêmen de bodes naturalmente infectados [Caprine lentivirus proviral DNA detection in semen of naturally infected bucks]. *Revista Brasileira de Reprodução Animal* 1999;23:420–1 [in Portuguese].
- [17] Andrioli A, Gouveia AMG, Pinheiro RR, Martins AS, Santos DO. Fatores de risco na transmissão do lentivírus caprino pelo sêmen [Risk factors in caprine lentivirus transmission through semen]. *Pesquisa Agropecuária Brasileira* 2006;41:1313–9 [in Portuguese].
- [18] Cruz JCM, Gouveia AMG, Souza KC, Braz GF, Teixeira BM, Heinemann MB, et al. Caprine arthritis-encephalitis virus (CAEV) detection in semen of endangered goat breeds by nested polymerase chain reaction. *Small Rumin Res* 2009;85:149–52.
- [19] Paula NRO, Andrioli A, Cardoso JFS, Pinheiro RR, Sousa FML, Souza KC, et al. Profile of the Caprine arthritis-encephalitis virus (CAEV) in blood, semen from bucks naturally and experimentally infected in the semi-arid region of Brazil. *Small Rumin Res* 2009;85:27–33.

- [20] Guedes MIMC, Souza JCA, Gouveia AMG. Infecção experimental em cabritos pelo vírus da artrite encefalite [Caprine arthritis encephalitis virus experimental infection in new-born kids]. *Arquivo Brasileiro de Medicina Veterinária e Zootecnia* 2001;53:15–20 [in Portuguese].
- [21] Pitcher DG, Saunders NA, Owen RJ. Rapid extraction of bacterial genomic DNA with guanidium thiocyanate. *Lett Appl Microbiol* 1989;8:151–6.
- [22] Narayan O, Clements JE, Strandberg JD, Cork LC, Griffin DE. Biological characterization of the virus causing leukoencephalitis and arthritis in goats. *J Gen Virol* 1980;50:69–79.
- [23] Nascimento EF, Santos RL. *Patologia da Reprodução dos Animais Domésticos*. Third edition. Rio de Janeiro: Guanabara Koogan; 2011.
- [24] Travassos C, Benoît C, Valas S, da Silva A, Perrin G. Detection of caprine arthritis encephalitis virus in sperm of experimentally infected bucks. *Vet Res* 1998;29:579–84.
- [25] Blacklaws BA. Small ruminant lentiviruses. Immunopathogenesis of visna-maedi and caprine arthritis and encephalitis virus. *Comp Immunol Microbiol Infect Dis* 2012;35:259–69.
- [26] Cousens C, Thonur L, Imlach S, Crawford J, Sales J, Griffiths DJ. Jaagsiekte sheep retrovirus is present at high concentration in lung fluid produced by ovine pulmonary adenocarcinoma-affected sheep and can survive for several weeks at ambient temperatures. *Res Vet Sci* 2009;87:154–6.
- [27] Martineau HM, Cousens C, Imlach S, Dagleish MP, Griffiths DJ. Jaagsiekte sheep retrovirus infects multiple cell types in the ovine lung. *J Virol* 2011;85:3341–55.